

Adenoidectomy with the coblator: a logical extension of radiofrequency tonsillectomy

MICHAEL S TIMMS, FRCS(ENG & ED), SUDIP GHOSH, MS, FRCS*, ALEXANDRA ROPER, MRCS*

Abstract

This paper describes a method of radiofrequency ablation of adenoid tissue using a coblator, comparing it with conventional and other newer methods of adenoidectomy. Its chief advantages are that it produces a bloodless field, precision of tissue removal and leads to less damage to surrounding tissues.

Key words: Adenoidectomy; Surgical Procedures; Operative; Radiofrequency

Introduction

Conventional adenoidectomy with curettage is currently the most widely practised method of adenoid surgery, but is not without its drawbacks. Blind curettage can traumatize the eustachian tubes, the septum and the cervical spine, and bleeding, though usually self-limiting, can occasionally be excessive and may require a post-nasal pack. Moreover, blind curettage cannot clear the adenoidal tissue within the posterior choanae, which is sometimes the most important cause of airway obstruction, nor can it fully remove the adenoid tissue from the sides of the eustachian tube orifices safely.

Experience with coblation tonsillectomy prompted the authors to perform adenoidectomy with the same equipment (EVac 70 Coblator™ wand) with gratifying results. This paper describes the technique of using this equipment to remove the adenoids under vision and without measurable blood loss, including the tissue in the posterior choanae and overlying the eustachian tube cushions. It can be easily performed by anyone familiar with the coblator system.

Method

The patient is placed in the adenoidectomy position with a Boyle–Davis gag positioned with Draffin's rods or other suspension devices. Suction catheters are used to elevate the soft palate and the nasopharynx is viewed with a laryngeal mirror throughout the procedure.

The EVac 70 wand is used as in tonsillectomy with comparable settings (ablation setting 9 and coagulation setting 3). The saline irrigation flow and suction are set at maximum. The adenoid tissue is removed by stroking the wand over it, gently indenting the surface and allowing the fronds of tissue to be sucked onto the tip of the instrument. To avoid blockage the wand tip is kept constantly in motion. Most vessels are coagulated during the adenoid ablation, but any that are missed can be sealed by a brief burst of coagulation. Lymphoid tissue overlying the eustachian cushions is carefully removed under vision by

short interrupted bursts of ablation energy. The wand will also reach beyond the posterior edge of the nasal septum to dissolve adenoid tissue obstructing the posterior choanae from within, and if necessary, the wand can be bent to the contour required. Figure 1 shows adenoidal tissue blocking the posterior choanae and the eustachian tube cushions, the picture taken just prior to starting the coblation. With this technique it is possible to remove just the adequate amount of adenoid tissue that is judged sufficient to relieve obstruction in the post-nasal space or eustachian tube orifices, and no attempt is made to remove tissue right down to the pre-vertebral muscle layer. In the senior author's hands, the first case took 15 min to complete, but after half a dozen or so procedures, the operating time has come down to about 5 min. No additional time is required for haemostasis, and therefore in our experience, it takes less total time than conventional adenoidectomy. Figure 2 shows the near bloodless field after removal of the adenoids. In all the cases performed by this technique so far, the blood loss has been less than 1ml.

Discussion

Conventional adenoidectomy with a curette, despite being relatively quick, simple and safe, has been known to be associated with a few well-documented problems. Blood loss, although rarely excessive, can occasionally be significant in very young children. Moreover, on occasions it can be difficult to control and post-nasal packs may have to be inserted, necessitating intubation in young children in the post-operative period. Newer techniques that have been described to significantly reduce per-operative blood loss include the suction coagulator adenoidectomy^{1,2} and the power-assisted microdebrider adenoidectomy.^{3–5} Following the senior author's extensive experience with the coblator radiofrequency tonsillectomy,⁶ the introduction of coblation to adenoidectomy was a logical extension, in view of the extremely low blood loss and other advantages discussed below.

Secondly, the fact that conventional adenoidectomy is a

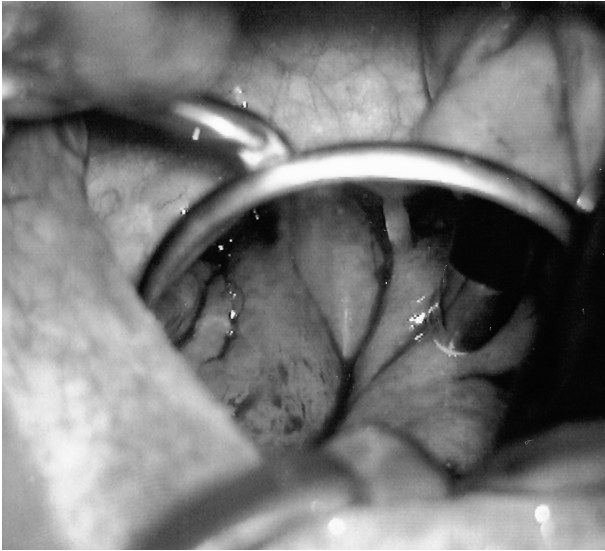

FIG. 1

Adenoids blocking posterior choanae and eustachian tube cushions, with the EVac 70 wand resting on it.

blind procedure implies that there is an increased likelihood of trauma to the eustachian tube orifices and the posterior end of the nasal septum. The use of the laryngeal mirror or the nasoendoscope makes tissue removal from the nasopharynx more precise and minimizes the likelihood of trauma. In addition, visualization makes it far easier to achieve a bloodless field using coblation or suction diathermy techniques. In one of our recent cases of nasal obstruction and rhinolalia aperta, it was possible to remove all tissue from the posterior choanae without further compromising palatal closure. Visualization thus enables precise removal of adenoid tissue, and several papers have described a partial adenoidectomy procedure under direct vision utilizing these newer techniques.^{7,8} We have found the use of the EVac 70™ coblation wand particularly efficacious in removing adenoid tissue localized inside the posterior choanae (difficult with conventional curetting) and in the lateral walls of the nasopharynx surrounding the eustachian tube orifices.

Our view about the use of coblation is that the shallow depth of penetration of energy and low tissue temperatures at the coblated interface means that there is very little surrounding tissue damage and fibrosis⁹ with preservation of tissue architecture.⁹ This makes it ideal for working near the delicate eustachian tube cushions and performing partial adenoidectomy particularly in submucous clefts of the palate in varying degrees. Although the precision and bloodlessness of the suction diathermy and coblation techniques are comparable, we believe that coblation causes much less underlying tissue damage than electrosurgery.¹⁰ A recent paper¹¹ highlighted the four-fold higher energy level with monopolar compared with bipolar diathermy, and indicated the use of monopolar suction diathermy as a risk factor for Grisel's syndrome (non-traumatic atlantoaxial joint subluxation) in a study of 721 adenoidectomies.

There would need to be special reasons to justify the expense of a coblation wand for an adenoidectomy alone (currently a wand costs approximately £100) but if one has already been opened for tonsillectomy then it makes sense, in the light of the authors' experience, to use it to perform an efficient and bloodless adenoidectomy. This is now the authors' practice in all such circumstances. In our opinion, coblation adenoidectomy is an attractive

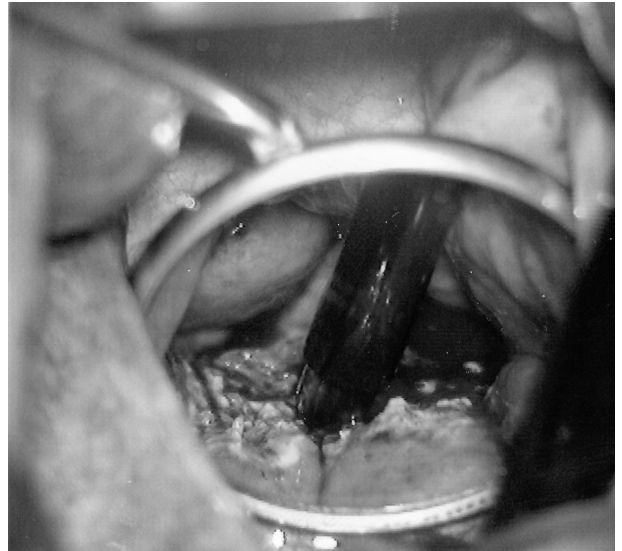


FIG. 2

Post-operative view of the nasopharynx after removal of all adenoid tissue, and showing the near-bloodless field.

alternative disposable instrument technique at the modern otolaryngologist's disposal.

References

- 1 Wynn R, Rosenfield RM. Outcomes in suction coagulator adenoidectomy. *Arch Otolaryngol Head Neck Surg* 2003;**129**:182-5
- 2 Walker P. Pediatric adenoidectomy under vision using suction-diathermy ablation. *Laryngoscope* 2001;**111**:2173-7
- 3 Elluru RG, Johnson L, Myer CM 3rd. Electrocautery adenoidectomy compared with curetting and power-assisted methods. *Laryngoscope* 2002;**112**(Pt 2 Suppl 100):23-5
- 4 Koltai PJ, Chan J, Younes A. Power-assisted adenoidectomy: total and partial resection. *Laryngoscope* 2002;**112**(8 Pt 2 Suppl 100):29-31
- 5 Sorin A, Bent JP, April MM, Ward RF. Complications of microdebrider-assisted powered intracapsular tonsillectomy and adenoidectomy. *Laryngoscope* 2004;**114**:297-300
- 6 Belloso A, Chidambaram A, Morar P, Timms MS. Coblation tonsillectomy versus dissection tonsillectomy: postoperative hemorrhage. *Laryngoscope* 2003;**113**:2010-13
- 7 Finkelstein Y, Wexler DB, Nachmani A, Ophir D. Endoscopic partial adenoidectomy for children with submucous cleft palate. *Cleft Palate Craniofac J* 2002;**39**:479-86
- 8 Rodriguez K, Murray N, Guarisco JL. Power-assisted partial adenoidectomy. *Laryngoscope* 2002;**112**(8 Pt 2 Suppl 100):26-8
- 9 Terk AR, Levine SB. Radiofrequency volume tissue reduction of the tonsils: case report and histopathologic findings. *Ear Nose Throat J* 2004;**83**:572,574,576-8
- 10 Plant RL. Radiofrequency treatment of tonsillar hypertrophy. *Laryngoscope* 2002;**112**(8 Pt 2 Suppl 100):20-2
- 11 Tschopp K. Monopolar electrocautery in adenoidectomy as a possible risk factor for Grisel's syndrome. *Laryngoscope* 2002;**112**(8 Pt 1):1445-9

Address for correspondence:

Mr M S Timms,
Department of Otolaryngology,
Blackburn Royal Infirmary,
Infirmary Street,
Blackburn BB2 3LR, UK.

E-mail: mtimms@uk-consultants.co.uk

Mr M S Timms takes responsibility for the integrity of the content of the paper.

Competing interests: None declared