

# Perioral Burns After Adenotonsillectomy

## A Potentially Serious Complication

Michael J. Nuara, MD; Albert H. Park, MD; Stephen C. Alder, PhD; Marshall E. Smith, MD; Steve Kelly, MD; Harlan Muntz, MD

**Objectives:** To evaluate an institutional experience with perioral burns after adenotonsillectomy and to survey the national experience of other pediatric otolaryngologists regarding this complication.

**Design:** A retrospective review of adenotonsillectomy cases from January 1, 1997, to December 31, 2005, was performed to determine the incidence, etiology, severity, and treatment of perioral burns. An online national survey of pediatric otolaryngologists was conducted in May 2006 to identify their experience with perioral burns.

**Setting:** A tertiary pediatric medical center.

**Participants:** We evaluated cases with patients younger than 18 years who developed a perioral burn during an adenotonsillectomy or tonsillectomy at Primary Children's Medical Center, Salt Lake City, Utah.

**Main Outcome Measures:** Institutional and national incidence, number of injuries per physician, technique used, severity of injury, and outcomes. Comparisons were made with respect to respondent experience and techniques used.

**Results:** Seven cases of perioral burn from a single institution were identified from 4327 procedures, with 1 injury requiring reconstructive surgery. The survey response rate was 101 of 298 invitations (33.9%). Sixty-one respondents reported a total of 124 perioral burns after adenotonsillectomy. Monopolar cautery was the most common technique associated with this injury ( $n=84$ ). Coblation was the second most common technique associated with perioral burns and represented 15 (12.1%) of the reported complications. A defective electrocautery device tip was the most commonly identified cause of burn ( $n=25$ ), followed by operator error ( $n=13$ ), conduction through a metal instrument ( $n=8$ ), and lack of insulation in a cautery device ( $n=7$ ). Coblation injury was attributed to direct heat transfer from the device shaft. No significant association with operator experience was noted. A total of 14 (11.3%) of the reported injuries were severe, resulting in the need for additional treatment.

**Conclusion:** Perioral burns are an underreported complication of adenotonsillectomy that can result in severe long-term morbidity.

*Arch Otolaryngol Head Neck Surg.* 2008;134(1):10-15

**A**DENOTONSILLECTOMY REMAINS one of the most commonly performed surgical procedures in the United States. Approximately 300,000 tonsillectomies are performed annually in the United States.<sup>1</sup> Reported complications associated with adenotonsillectomy include hemorrhage, pain, dehydration, airway obstruction secondary to edema, pharyngeal stenosis, voice change, and velopharyngeal insufficiency.<sup>2-4</sup> Perioral burns from adenotonsillectomy procedures are rarely cited in the literature. Reilly et al<sup>5</sup> reported a case of oral commissure injury due to cautery malfunction. Additional reports<sup>6,7</sup> regarding perioral injury during oral procedures appear in the dental literature. During a 9-year period, we noted 7 cases of perioral burns at our institution. We therefore hypothesize that this

complication is underreported. The objectives of this study are to present our institutional experience with this condition and to determine the relative national incidence via a survey of pediatric otolaryngologists in the United States.

## METHODS

### PATIENT SELECTION

Cases with patients younger than 18 years who developed a perioral burn during an adenotonsillectomy or tonsillectomy at Primary Children's Medical Center (PCMC), Salt Lake City, Utah, between January 1, 1997, and December 31, 2005, were evaluated using university billing records and the PCMC medical center quality assurance database. For each procedure, the indications for surgery and operative technique were recorded.

**Author Affiliations:** Division of Otolaryngology-Head and Neck Surgery (Drs Nuara, Park, Smith, and Muntz) and Department of Family and Preventive Medicine (Dr Alder), The University of Utah, Bountiful. Dr Kelly is in private practice in Bountiful.

**Table 1. Perioral Burns Treated at Primary Children's Medical Center**

Patient No.	Age	Procedure	Complications	Treatment	Follow-up
1	3 y	T/A	Erythema at commissure noted in PACU < 1 h after procedure	Antibiotic ointment	Erythema resolved after 1 mo
2	5 y	PET, T/A	Tongue burn noted 3 h after procedure; swollen, red across tongue	None	Resolved in a few weeks
3	4 y	Adenoidectomy, PET	1/2 x 3/4-in abrasion noted postoperatively in right lower lip	Burn Unit consultation; silicone patch; massage; ointment; plastic surgery consultation	Persistent scar required reconstructive surgery 1 y later
4	4 y	T/A, tympanoplasty, skin tag removal	Blisters noted postoperatively at corner of mouth	Antibiotic ointment	Resolved after 5 d
5	4 y	PET, T/A	2 Blisters noted 3 h after procedures, left upper lip and right commissure	Plastic surgery consultation	Resolved after 5 d
6	7 y	T/A	Left oral commissure burns 1.5 cm large noted in OR involving vermillion and buccal mucosa; Bovie tip changed before proceeding	Burn Unit consultation; antibiotic ointment; stretching exercises	Persistent scar
7	21 mo	MDL, bronchoscopy, T/A	Right lower lip and commissure burn noted in recovery room	Antibiotic ointment; Burn Unit consultation; stretching and scar massage	Persistent scar

Abbreviations: MDL, microscopic direct laryngoscopy; OR, operating room; PACU, Post Anesthesia Care Unit; PET, pressure equalization tube; T/A, tonsillectomy and adenoidectomy.

**SURVEY**

For the next portion of the study, pediatric otolaryngologists who were members of the American Society of Pediatric Otolaryngology (ASPO) were surveyed. Surveys were conducted by e-mail invitation and online submission to ASPO members. Two hundred ninety-eight e-mails were sent, and 101 completed surveys were returned, for a response rate of 33.9%. Data collected included the operative technique, the number of adenotonsillectomies performed per week, the number of perioral burn injuries detected, and the treatment and outcome of the affected patients. Approval from The University of Utah institutional review board was obtained for both portions of this study.

**STATISTICAL ANALYSIS**

Survey data were captured using an HTML-based online survey posted on the ASPO Web site and analyzed using SPSS statistical software, version 14.0 (SPSS Inc, Chicago, Illinois). Simple frequencies and percentages were calculated for all variables of interest. Physicians were grouped into 1 of 3 experience categories based on years practicing pediatric otolaryngology (group 1, 1-10 years; group 2, 11-15 years; and group 3, > 15 years). Percentages, Pearson  $\chi^2$  tests, Kruskal-Wallis tests, and 1-way analysis of variance were used to compare the 3 groups for procedures per week, development of burns, mean complications, and extent of injury in affected children.

**RESULTS**

A sample case report is presented to highlight some of the common important issues noted in our study.

**CASE REPORTS**

A 4-year-old girl with a history of recurrent otitis media underwent an adenoidectomy and placement of tympanostomy tubes. After tube placement, a standard Crowe-Davis retractor and medium-sized tongue blade were used to obtain exposure of the oropharynx. Small-caliber rubber catheters were placed through the nasal cavity and secured at the lip to retract the soft palate and uvula. The adenoids were removed with an insulated suction cauter at 30 W.

Postoperatively, while in the recovery room, the patient was inconsolable and the nursing staff noticed a burn on the right lower lip skin, vermillion, and buccal mucosa with clear exudate and bleeding. The family was notified about the perioral burn, a consultation with the Burn Unit was obtained, and the parents were instructed to apply bacitracin antibiotic ointment twice daily. By the third postoperative day, the upper lip area was healing but had some continued exudate.

Three weeks after surgery, a resulting scar was becoming more obvious, with some tethering at the oral commissure. Scar massage was suggested, along with the use of a silicone patch. The scar was still noticeable 1 year after surgery. The scar measured 1.0 x 0.3 cm and was firm and raised. Two years after the adenotonsillectomy, the child underwent a scar revision of the oral commissure.

During a 9-year period, 6 other cases of perioral burns after tonsillectomy or adenoidectomy were noted at our institution. The pediatric otolaryngologists at the PCMC

**Table 2. Complications as a Function of Years in Practice**

	Years Practicing Pediatric Otolaryngology			P Value
	1-10 (n=21)	11-15 (n=26)	15 (n=52) <sup>a</sup>	
Procedures per week: No. (%)				
1	0	0	2 (3.9)	42 <sup>b</sup>
1-5	3 (14.3)	10 (38.5)	13 (25.5)	
6-10	12 (57.1)	10 (38.5)	21 (41.2)	
>10	6 (28.6)	6 (23.1)	15 (29.4)	
Ever developed burn: No. (%)				
Yes	12 (57.1)	17 (65.4)	32 (61.5)	85 <sup>c</sup>
No	9 (42.9)	9 (34.6)	20 (38.5)	
Complications: mean No.	0.9	1.4	1.4	44 <sup>d</sup>
Complications: mean No. <sup>e</sup>	1.5	2.2	2.2	48 <sup>d</sup>
Extent of injury of affected child: No. (% of total burns)				
First degree (minor)	9 (75.0)	13 (76.5)	25 (78.1)	88 <sup>b</sup>
Second degree	2 (16.7)	0	6 (18.8)	
Third degree (scarring)	1 (8.3)	4 (23.5)	1 (3.1)	

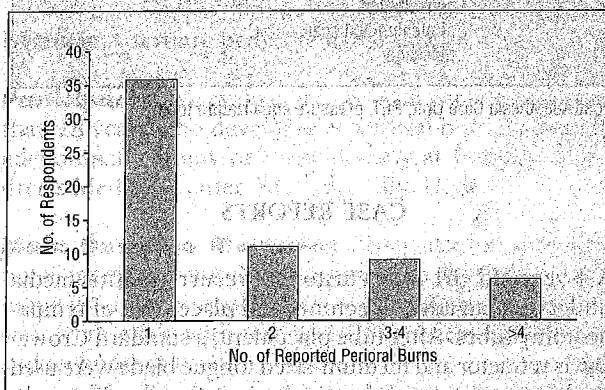
<sup>a</sup>Numbers may not sum to total owing to missing data.

<sup>b</sup>Kruskal-Wallis test.

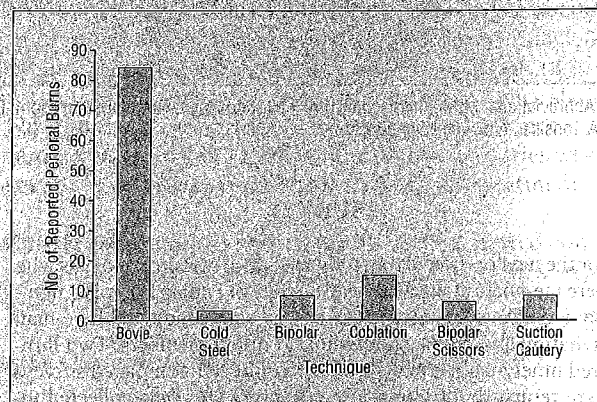
<sup>c</sup>Pearson  $\chi^2$  test.

<sup>d</sup>One-way analysis of variance test.

<sup>e</sup>Mean only for those who ever had a patient who developed a burn.



**Figure 1.** Number of perioral burn complications reported by survey respondents.



**Figure 2.** Number of perioral burns reported expressed by technique used when complication occurred.

performed 4327 tonsillectomies, adenoidectomies, or both during the study period. This complication resulted in a rate of 0.16% or approximately 1 of every 618 cases.

**Table 1** gives the details of each patient's treatment course. Four patients underwent consultation with either a plastic surgeon or the Burn Unit. Three of 4 patients who underwent consultation developed a permanent scar. One child was treated with silicone sheeting, 2 performed stretching exercises to prevent microstomia, and 1 underwent scar revision at the oral commissure.

**SURVEY RESULTS**

Two hundred ninety-eight e-mails were sent and 101 completed surveys were returned, for a response rate of 33.9%.

**Table 2** indicates the degree of experience of the respondents. Only 1 respondent had been in practice for less than 6 years. Most physicians were relatively experienced and had been in practice for more than 10 years.

In terms of number of procedures, most of the respondents performed more than 6 adenotonsillectomy procedures per week. Sixty-one (60.4%) reported having a patient develop a perioral burn after an adenotonsillectomy. Using the responses for years of experience and procedures performed per week, the total number of procedures accounted for in the responses can be estimated as between 300,000 and 1.25 million procedures. Given a total of 124 reported perioral burn complications, we can estimate a relative frequency of perioral burn complications between 0.01% and 0.04%.

Of those respondents who reported burn complications, 36 (59.0%) reported only 1 such complication (**Figure 1**). Six (9.8%) reported more than 4 complications. A total of 124 complications from all respondents were reported. Bovie cautery was the most common technique that was associated with a perioral burn (n=84), whereas cold steel was the least commonly reported technique associated with a perioral burn (n=3) (**Figure 2**).




Figure 3. Perioral burn complications reported expressed as a function of proposed cause.




Figure 4. Exposed portion of the electrocautery probe, which may cause an injury.

No further information on how the cold steel technique would result in a burn was provided. Whether cautery was additionally used to assist with hemostasis was not reported in the survey responses. Aside from cold steel, bipolar techniques and suction cautery alone represented the techniques least likely to be associated with burns (3.7% and 4.9%, respectively). A specific cause of perioral burn was postulated for 61 cases (49.2%). These findings are shown in **Figure 3**. For the remaining 63 cases, no specific cause was identified. A defective electrocautery device tip was the most frequently noted cause (20.2%; n=25) (**Figure 4**). Operator error was noted by 10.5% of respondents as the second most commonly identifiable cause (n=13).

The mean number of complications was similar for all levels of experience (Table 2). Although more severe burns were reported by those with 11 to 15 years of experience compared with those with more or less years of experience, this finding was not statistically significant ( $P=.88$ ). A total of 81.4% of injuries were first-degree burns, whereas 11.0% were third-degree burns that resulted in scarring. Antibiotic ointment was the most commonly reported treatment. Other treatments were reported for the 15 cases that qualified as third-degree burns, including scar revision, stents, and steroid injections (**Figure 5**).

Overall, monopolar cautery was associated with the greatest number of severe burns (n=7). However, the total number of reported cases for each technique was too small to determine whether any particular technique resulted in a statistically significantly greater rate of third-degree

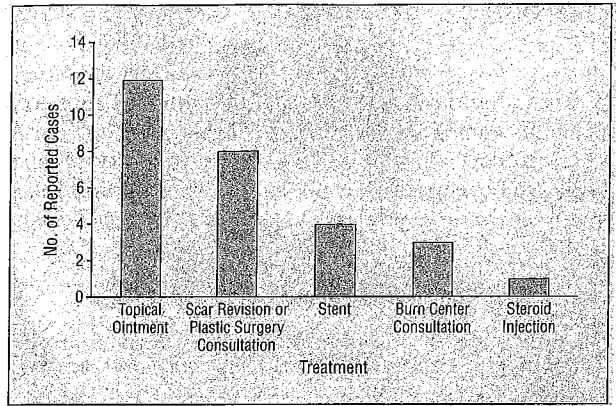


Figure 5. Further treatments reported by respondents for perioral burn complications.

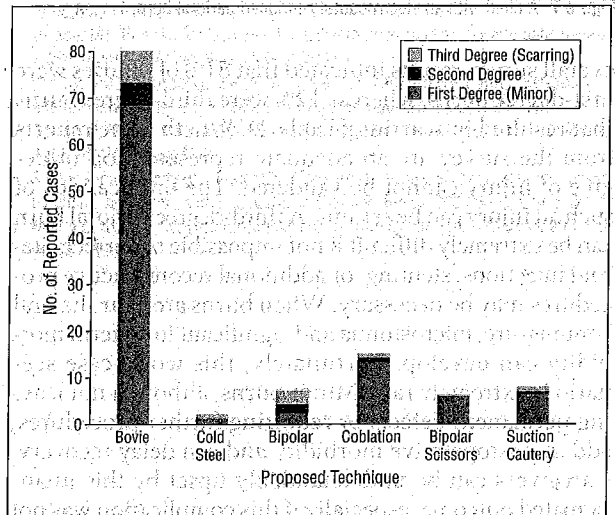


Figure 6. Perioral burn complications reported expressed by degree of burn as a function of the technique used.

burns. Of the 80 reported burns during the use of monopolar cautery, 8.8% (n=7) were third-degree burns. Bipolar technique was associated with third-degree burns in 2 of the 7 cases. Coblation caused 1 severe burn of the 13 reported complications for this technique (**Figure 6**).

#### COMMENT

Perioral burns are a rarely reported complication of tonsillectomy, with only 1 reported case in the otolaryngology literature<sup>5</sup> and no indication of incidence. In the experience at our institution, we found an overall incidence of 1 per 618 cases or 0.16%. Survey results indicated that the incidence of perioral burns was 0.01% to 0.04%. This survey was not validated, and the data are likely to have been subject to significant recall bias. Compared with the data collected at the PCMC, the national incidence is 4-fold lower. Compared with other complications, such as dehydration and bleeding, perioral burns represent a rare occurrence.

The rate of severe burns nationally was considerably less than what has been experienced at our institution, where 3 of the 7 complications resulted in scarring. The

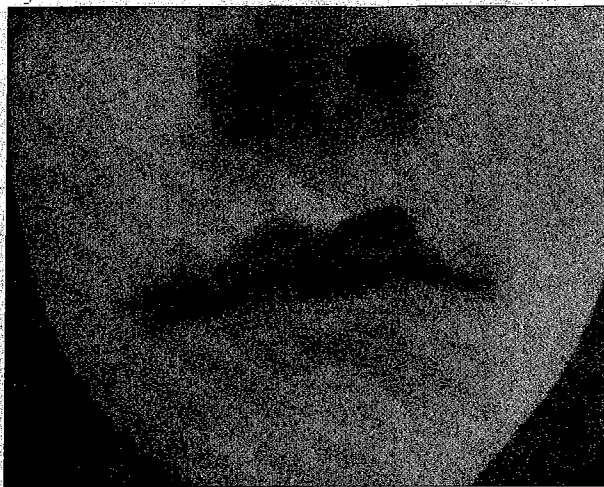


Figure 7. A child with an electrocautery-induced perioral burn.

overall survey results indicated that 81% of injuries were first-degree burns, whereas 12% were third-degree burns that resulted in scarring (Table 2). Whether the reports from the survey are an adequate representation of degree of injury cannot be validated. The implications of such an injury can be serious. A third-degree perioral burn can be extremely difficult if not impossible to correct. Steroid injections, stenting, or additional reconstructive procedures may be necessary. When burns are near the oral commissure, microstomia and significant long-term morbidity can develop. Fortunately, this worst-case scenario is extremely rare. Minor burns, although not leaving permanent defects or requiring further procedures, add to postoperative morbidity and can delay recovery. Caregivers can be understandably upset by this unanticipated outcome, especially if this complication was not discussed during preoperative counseling (Figure 7). At our institution, 1 of these cases resulted in medicolegal action to the practicing otolaryngologist.

Bipolar techniques and suction cautery resulted in relatively few injuries. Because there was no information obtained on the number of individual techniques performed, no conclusion about the rate of perioral burns by specific surgical technique can be made. Respondents indicated that the cause of the injury was usually attributed to a defect in an electrocautery device (41% when indicated and 20% overall). Sixty-three burns had no cause associated with them, although every technique was associated with an injury. When asked whether the occurrence of a perioral burn complication had led to a change in technique, the respondents varied from completely abandoning a specific technique to changing the device used (such as a monopolar tip) to adjusting the approach taken with resident surgeon participation and diligence in precaution. Interestingly, although some surgeons advocated a specific technique being safer, others would assert that the same technique caused injury.

At our institution, we have become vigilant about avoiding perioral burns caused by any surgical technique. In the case presented previously, the operating surgeon, at the completion of the procedure, noted a small gap of 1 to 2 mm of exposed cautery tip between the hand-piece and the protective wrap (Figure 4). Even after the

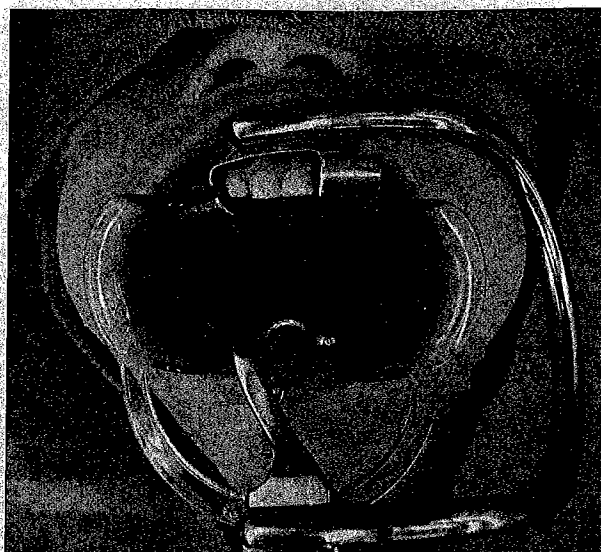


Figure 8. Cheek retractor that provides improved exposure and perioral protection.

surgeon checked to be sure the tip was fully inserted, the gap remained. This gap presumably provided an area for the electric current to contact the child's oral commissure. It is important that electrocautery tips be checked by the surgeon to ensure maximal insertion and absence of any exposed conducting portions. Many of the surgeons have switched to a "guarded" Bovie tip to avoid potential perioral burns. Such a product, introduced by Valley Laboratory (Boulder, Colorado), may not require as much vigilance in checking for an exposed conducting surface. Unfortunately, any device can cause perioral burns. One of the authors (A.H.P.) has been using a disposable plastic cheek retractor to protect the most vulnerable regions of the lip from inadvertent trauma (Figure 8). This device improves intraoral exposure of the tonsils and may ameliorate potential injury to the lateral oral commissure. We have also used this device for other procedures that require a transoral approach, such as tongue reduction, mandibular maxillary fixation for fractures, or submandibular rerouting procedures, because of the excellent exposure it provides. Meticulous technique and frequent inspection of the operating equipment should be sufficient to avoid most perioral burn complications.

Preoperative counseling has been advocated for these procedures. Mistry and Kelly<sup>8</sup> surveyed patients and otolaryngologists regarding the use of informed consent in discussing potential complications of tonsillectomy. In this report, 4% of physicians believed that perioral burns were a potentially serious complication compared with 14% of parents interviewed. This difference was not statistically significant, yet it illustrates the degree of concern regarding this complication among parents. Resultant medicolegal action for one child and reconstructive surgery in another at the PCMC indicate the potential serious consequences to the patient, family, and physician.

In conclusion, there is a paucity of literature that addresses the potential complication of a perioral burn during adenotonsillectomy. This injury can be a serious complication that can delay recovery and has the

potential for permanent injury. Fortunately, these occurrences are rare. However, because tonsillectomy remains one of the most frequently performed procedures, measures to avoid this complication exist and should be considered for every case. In addition, consideration should be given to discussing this potential complication during preoperative counseling for informed consent.

**Submitted for Publication:** June 31, 2007; final revision received July 13, 2007; accepted July 30, 2007.

**Correspondence:** Albert H. Park, MD, Division of Otolaryngology-Head and Neck Surgery, The University of Utah School of Medicine, 50 N Medical Dr, 3C 120, Salt Lake City, UT 84143. (albert.park@intermountainmail.org)

**Author Contributions:** Drs Nuara and Park had full access to all the data in the study and take responsibility for the integrity of the data and the accuracy of the data analysis. *Study concept and design:* Park, Alder, and Muntz. *Acquisition of data:* Nuara, Park, Kelly, and Muntz. *Analysis and interpretation of data:* Nuara, Park, and Smith. *Drafting of the manuscript:* Nuara and Park. *Critical revision of the manuscript for important intellectual content:* Nuara, Park, Alder, Smith, Kelly, and Muntz. *Statistical analysis:* Alder. *Administrative, technical, and material support:* Nuara and Park. *Study supervision:* Park, Smith, and Muntz.

**Financial Disclosure:** None reported.

**Presentations:** This article was presented at The American Society of Pediatric Otolaryngology 2007 Annual Meeting; April 29, 2007; San Diego, California.

**Additional Information:** This article received a second place Charles F. Ferguson Clinical Research Award.

## REFERENCES

1. Shinhar S, Scotch BM, Belenky W, Madgy D, Hauptert M. Harmonic scalpel tonsillectomy versus hot electrocautery and cold dissection: an objective comparison. *Ear Nose Throat J.* 2004;83(10):712-715.
2. Baker K. An overview of current techniques for tonsillectomy [review]. *ORL Head Neck Nurs.* 2006;24(3):8-12.
3. Shine NP, Coates HL, Lannigan FJ. Obstructive sleep apnea, morbid obesity, and adenotonsillar surgery: a review of the literature. *Int J Pediatr Otorhinolaryngol.* 2005;69(11):1475-1482.
4. Brigger MT, Brietzke SE. Outpatient tonsillectomy in children: a systematic review. *Otolaryngol Head Neck Surg.* 2006;135(1):1-7.
5. Reilly MJ, Milmoe G, Pena M. Three extraordinary complications of adenotonsillectomy. *Int J Pediatr Otorhinolaryngol.* 2006;70(5):941-946.
6. Ozelik O, Haytac MC, Akkaya M. Iatrogenic trauma to oral tissues. *J Periodontol.* 2005;76(10):1793-1797.
7. Santos-Pinto L, Campos JA, Giro EM, Cordeiro R. Iatrogenic chemical burns caused by chemical agents used in dental pulp therapy. *Burns.* 2004;30(6):614-615.
8. Mistry D, Kelly G. Consent for tonsillectomy. *Clin Otolaryngol Allied Sci.* 2004;29(4):362-368.